

Peerbooms, J, et al, Positive Effect of an Autologous Platelet Concentrate in Lateral Epicondylitis in a Double - Blind Randomized Controlled Trial, *American Journal of Sports Medicine*, 2010; 39:255-261

This double-blind randomized controlled study evaluated the effectiveness of concentrated autologous platelet injections compared with corticosteroid injections for treatment of chronic lateral epicondylitis with 12 month follow-up

Methods

- 100 patients with chronic lateral epicondylitis were randomly assigned in the PRP group (51) or the corticosteroid group (49)
- All procedures used the same injection procedures
- Criteria for participation included lateral epicondylitis for longer than 6 months and pain of at least 50 on a visual analog score for pain
- Before 6 months of the trial, patients were treated with cast immobilization, injections with corticosteroids, or physiotherapy
- 30 mL of blood was collected from both the treatment and control groups
- 3 ml total was injected; 1 mL was injected directly into the area of maximum tenderness, the balance was injected using a peppering technique into the common extensor tendon
- No activating agent for the PRP was used
- Primary outcome parameters included visual analog scores and DASH outcome measure scores
- Successful treatment was defined as more that a 25% reduction in visual analog or DASH scores without a reintervention after 1 year

Results

- According to the VAS scores ($p < 0.001$) and DASH scores ($p = 0.005$), 37 of the 51 (73%) in the PRP group were successful verses 24 of 49 (49%) in corticosteroid group
- The corticosteroid control group was better initially and then declined, whereas the PRP treatment group progressively improved
- If criteria for success was set at 50% or 75% improvements of both scores (instead of 25% improvement), the results still show significant differences between the treatment and control groups
- There were no reported complications – e.g. fever, rashes, infection, etc

Conclusions/Key Points

- A single injection of PRP reduces pain and increases function significantly more than the effect of corticosteroid injection

Positive Effect of an Autologous Platelet Concentrate in Lateral Epicondylitis in a Double-Blind Randomized Controlled Trial

Platelet-Rich Plasma Versus Corticosteroid Injection With a 1-Year Follow-up

Joost C. Peerbooms,* MD, Jordi Sluimer,[†] MD, Daniël J. Bruijn,* PhD, and Taco Gosens,^{†‡} PhD
From the *Department of Orthopaedic Surgery, HAGA Hospital, The Hague, Netherlands, and
[†]Department of Orthopaedic Surgery, St Elisabeth Hospital, Tilburg, Netherlands

Background: Platelet-rich plasma (PRP) has shown to be a general stimulation for repair.

Purpose: To determine the effectiveness of PRP compared with corticosteroid injections in patients with chronic lateral epicondylitis.

Study Design: Randomized controlled trial; Level of evidence, 1.

Patients: The trial was conducted in 2 teaching hospitals in the Netherlands. One hundred patients with chronic lateral epicondylitis were randomly assigned in the PRP group (n = 51) or the corticosteroid group (n = 49). A central computer system carried out randomization and allocation to the trial group. Patients were randomized to receive either a corticosteroid injection or an autologous platelet concentrate injection through a pepping technique. The primary analysis included visual analog scores and DASH Outcome Measure scores (DASH: Disabilities of the Arm, Shoulder, and Hand).

Results: Successful treatment was defined as more than a 25% reduction in visual analog score or DASH score without a re-intervention after 1 year. The results showed that, according to the visual analog scores, 24 of the 49 patients (49%) in the corticosteroid group and 37 of the 51 patients (73%) in the PRP group were successful, which was significantly different ($P < .001$). Furthermore, according to the DASH scores, 25 of the 49 patients (51%) in the corticosteroid group and 37 of the 51 patients (73%) in the PRP group were successful, which was also significantly different ($P = .005$). The corticosteroid group was better initially and then declined, whereas the PRP group progressively improved.

Conclusion: Treatment of patients with chronic lateral epicondylitis with PRP reduces pain and significantly increases function, exceeding the effect of corticosteroid injection. Future decisions for application of the PRP for lateral epicondylitis should be confirmed by further follow-up from this trial and should take into account possible costs and harms as well as benefits.

Keywords: lateral epicondylitis; platelet rich plasma; corticosteroids; pain; function

Lateral epicondylitis is the most commonly diagnosed condition of the elbow, affecting approximately 1% to 3% of the population. The condition mostly occurs in patients whose activities require strong gripping or repetitive wrist movements. Individuals between the ages of 35 and 50 years

are at high risk. The dominant arm is most frequently affected.^{7,8,13}

The cause of lateral epicondylitis is unknown. It is thought that lesions occur in the common origin of the wrist and finger extensors on the lateral epicondyle owing to a combination of mechanical overloading and abnormal microvascular responses.^{12,19,24}

Numerous methods have been advocated for treating elbow tendinosis, including rest, nonsteroidal anti-inflammatory medication, bracing, physical therapy, extracorporeal shock wave therapy, and botulism toxin injection. Injection of corticosteroids (once considered the gold standard but now controversial), whole blood injections, and various types of surgical procedures have also been recommended.^{2,3,16,18,25}

[‡]Address correspondence to Taco Gosens, PhD, St Elisabeth Hospital, Hilvarenbeekseweg 60, Tilburg, 5022 GC, Netherlands (e-mail: t.gosens@elisabeth.nl).

No potential conflicts of interest declared.

In an animal model, the addition of growth factors to the ruptured tendon has been shown to increase the healing of the tendon.^{1,11} In humans, it has been shown that the injection of whole blood into the tendon decreases the pain.³

Platelet-rich plasma (PRP) is promoted as an ideal autologous biological blood-derived product that can be exogenously applied to various tissues, where it releases high concentrations of platelet-derived growth factors that enhance wound healing, bone healing, and tendon healing.¹⁴ In addition, PRP possesses antimicrobial properties that may contribute to the prevention of infections.⁵ When platelets become activated, growth factors are released and initiate the body's natural healing response.

In a double-blind randomized trial, we investigated whether injection of concentrated autologous platelets improves the outcome of patients with lateral epicondylitis more so than corticosteroid injection. The primary outcome parameters were pain and daily use of the elbow.

METHODS

This double-blinded randomized trial included 100 consecutive patients with lateral epicondylitis scheduled for injection therapy in 2 Dutch training hospitals between May 2006 and January 2008.

All procedures used the same injection procedure, performed by an orthopaedic consultant or a supervised orthopaedic resident. Criteria for participation included lateral epicondylitis for longer than 6 months and pain of at least 50 on a visual analog score (VAS) for pain (0, no pain; 100 maximum pain possible). Lateral epicondylitis was defined as pain over the lateral epicondyle on direct palpation and pain in that area during resisted wrist extension. All affected elbows were screened with radiography and all proved to be normal, except for some calcifications of the common extensor origin. Sonography and magnetic resonance imaging were not standardly used. Patients had a clinical diagnosis of lateral epicondylitis, or lateral elbow pain increased by pressure on the lateral epicondyle and during resisted extension of the wrist. All patients suffered for more than 6 months. Before 6 months of the trial, they were treated with cast immobilization, injections with corticosteroids, or physiotherapy.

Exclusion criteria were as follows: age less than 18 years, pregnancy, history of carpal tunnel syndrome or cervical radiculopathy, and systemic disorders such as diabetes, rheumatoid arthritis, and hepatitis. Also, patients were excluded if they had been treated for lateral epicondylitis with surgical intervention or with a corticosteroid injection in the past 6 months.

The primary endpoint was a 25% reduction in the VAS score or DASH Outcome Measure score (DASH: Disabilities of the Arm, Shoulder, and Hand) without a reintervention after 1 year. In the current study, we tested the hypothesis that the injection of concentrated autologous platelets increases the healing of patients with tendinitis compared with those treated with a steroid injection.

Statistical data were collected to determine the power of both groups. Successful treatment in the PRP group was

determined by using the results of Mishra and Pavelko.¹⁰ In this study, 93% of the patients with chronic lateral epicondylitis that received PRP were considered successful—that is, with more than a 25% decrease in pain. Successful treatment in the control group was determined by using the results of Hay and colleagues,⁶ who studied the effect of corticosteroid injections for chronic lateral epicondylitis. Full recovery or decrease in complaints without complications was seen in 65% of the patients in the corticosteroid group.

With a bilateral alpha of .05 and a power of 90% ($p_1 = .93$ and $p_2 = .65$), 42 patients per group are necessary to measure the difference with the chi-square test. To correct for the patients who were lost to follow-up, we included a minimum of 50 patients in each group. The Medical-Ethical Committee and the National and Institutional Review Board approved the study.

Randomization

Randomization was performed after patients were deemed eligible and had provided informed consent. Patients were randomly allocated to the concentrated autologous platelet group (PRP group) or the corticosteroid group (control group). A computer using block randomization of 10 patients was used to create a randomization schedule. Treatment assignments (placed in sequentially numbered opaque envelopes) were assigned by the trial managers, who also arranged the facilities needed for the procedure.

PRP Preparation

In the group randomized to receive PRP, the patient's own platelets were collected with the Recover System (Biomet Biologics, Warsaw, Indiana). This device uses a desktop-size centrifuge with disposable cylinders to isolate the platelet-rich fraction from a small volume of the patient's anticoagulated blood, drawn at the time of the procedure.

As part of the double-blind procedure, blood was also collected from the patients in the control group. In sum, 27 mL of whole blood was collected from the uninvolved arm into a 30-mL syringe that contained 3 mL sodium citrate. The platelet-rich fraction was prepared according to the instructions of the Recover System. Approximately 3 mL PRP was obtained for each patient. The PRP was then buffered to physiologic pH using 8.4% sodium bicarbonate, and bupivacaine hydrochloride 0.5% with epinephrine (1:200000) was added. No activating agent was used. After masking the tubes with opaque tape, the investigator returned and injected 3 mL of this PRP into the patient. The total time from blood draw to injection in the patients was about 30 minutes. No specialized equipment was required, other than the centrifuge to process the Recover disposable cylinders. All the procedures were performed in the same office setting by an independent person certified for blood management, without the investigator or the patient present.

Injection Technique. Approximately 1 mL of PRP or corticosteroids (kenacort 40 mg/mL triamcinolon acetonide) with bupivacaine hydrochloride 0.5% with epinephrine

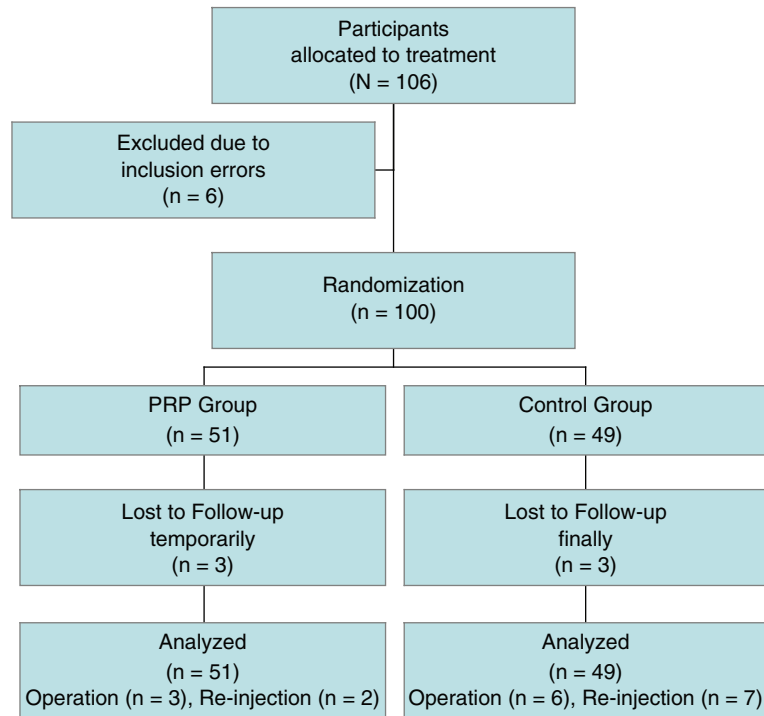


Figure 1. Flow diagram of a trial of injection therapy for chronic lateral epicondylitis. The diagram includes the number of patients actively followed up at different times during the trial.

(1:200000) was injected directly into the area of maximum tenderness. Then, using a 22-gauge needle and a peppering technique, the investigator injected the remaining PRP or corticosteroids with bupivacaine hydrochloride 0.5% with epinephrine (1:200000, \pm 4 mL) into the common extensor tendon. This technique involved a single skin portal and 5 penetrations of the tendon.

Postprocedure Protocol. Immediately after the injection, the patient was kept in a supine position without moving the arm for 15 minutes. Patients were sent home with instructions to rest the arm for approximately 24 hours. If necessary, patients were allowed to use acetaminophen, but the use of nonsteroidal anti-inflammatory medication was prohibited. After 24 hours, patients were given a standardized stretching protocol to follow for 2 weeks under the supervision of a physiotherapist. A formal eccentric muscle- and tendon-strengthening program was initiated after this stretching. At 4 weeks after the procedure, patients were allowed to proceed with normal sporting or recreational activities as tolerated. The VAS and DASH function scores were measured before injection and at 4, 8, 12, 26, and 52 weeks after injection. The DASH score is a validated upper limb functional score.²²

Statistical Analysis

All data analysis was carried out according to a preestablished analysis plan, on a last-observation-carried-forward basis. The categorical values are compared with the Pearson chi-square test. The preoperative continuous variables

are compared with the *t* test. The VAS and DASH scores are compared with an analysis of variance with repeated measurements test. The significance level was set at $P = .05$ for all tests, and SPSS 16.0 was used.

RESULTS

From May 2006 to January 2008, a total of 100 eligible patients with lateral epicondylitis were randomized into groups. Eight patients were lost to follow-up or had incomplete data sets; however, they needed no reintervention (Figure 1). Their data are included in the analysis until their last visit. Analysis of the demographics (sex, side, and center) between the protocol-compliant patients and those lost to follow-up showed no significant differences (Table 1).

The mean patient age was 47 years. There were 48 men and 52 women. The study included 63 patients with lateral epicondylitis on the right elbow and 37 patients with symptoms on the left elbow. The ratio between dominant and nondominant side was according to the literature: 65%. In most cases, the dominant side was involved.²³ The ratio was equally distributed. The activity level of the patients, preintervention and postintervention, has been noted in the DASH score.

Eighteen patients needed a reintervention. The patients who needed a reintervention were all scored as *nonsuccessful*. Between the 2 hospitals, there were no significant differences between the protocol-compliant patients and the reintervention patients ($P = .168$). The primary analysis was conducted on a carried-forward principle and involved 100 patients.

TABLE 1
Patient Demographics

	Corticosteroid	Platelet-Rich Plasma	<i>P</i>
Number	51	49	
Age, y	47.3 ± 7.6	46.9 ± 8.4	.797 ^a
Sex: male, female	25, 26	23, 26	.840 ^b
Side: right, left	32, 19	31, 18	.957 ^b
Lost to follow-up	1	3	.700 ^b
Reinterventions	13	5	.970 ^b

^a*t* test.

^bChi-square test.

In total, 18 reinterventions or operations were needed after an average of 5 months (range, 2-6 months). In the PRP group, 3 patients obtained an operation and 2 patients a reinjection with corticosteroids. In the corticosteroid group, 6 patients required an operation, 1 a reinjection with corticosteroid, and 6 a reinjection with PRP after 6 months of follow-up (Table 2). The percentages of reintervention did not depend on age, gender, side, treatment, or preoperative VAS or DASH score.

Six months after the initial treatment, the patients who were operated had VAS and DASH scores (respectively, 54.3 ± 26 and 112.2 ± 75.2) that were significantly worse than those of the nonoperated patients (*P* = .04). The patients needing a second injection had comparable VAS and DASH scores (60.6 ± 29 and 94.6 ± 62.2; *P* = .0196) as the patients who did not have a second injection.

Initially, the PRP-treated patients had a mean VAS score of 70.1 ± 15.1 and a mean DASH score of 161.3 ± 62.3. The control patients had a mean VAS score of 65.8 ± 13.8 and a mean DASH score of 131.2 ± 58.2. Four weeks after the procedure, PRP-treated patients reported a mean improvement of 21% in their VAS scores (70.1 to 55.4) compared with the initial values, whereas the corticosteroid-treated patients reported a 32.8% improvement (65.8 to 44.2; *P* = .077) (Figure 2). Also, after 4 weeks, DASH scores had improved 15.7% (161.3 to 135.9) in PRP patients versus a 25.8% improvement (131.3 to 97.4) in corticosteroid-treated patients (*P* = .469) (Figure 3).

Eight weeks after the procedure, PRP-treated patients reported a mean improvement of 33.1% (70.1 to 46.9) in their VAS scores compared with the initial values, whereas the corticosteroid-treated patients reported a 34.8% improvement (65.8 to 42.9; *P* = .818) (Figure 2). After 8 weeks, DASH scores improved 29.7% (161.3 to 113.4) in PRP patients versus a 35.5% improvement (131.26 to 84.7) in corticosteroid-treated patients (*P* = .999) (Figure 3).

Twelve weeks after the procedure, PRP-treated patients reported a mean improvement of 44.8% (70.1 to 38.7) in their VAS scores compared with the initial values, whereas the corticosteroid-treated patients reported a 32.8% improvement (65.8 to 44.2; *P* = .206) (Figure 2). Also, after 12 weeks, DASH scores had improved 43.0% (161.3 to 92.0) in PRP patients versus a 29.8% improvement (131.3 to 92.2) in corticosteroid-treated patients (*P* = .060) (Figure 3).

TABLE 2
Flow Chart of Patients

	Corticosteroid Group	Platelet Group	Total
Free of complications	35	43	78
Temporarily lost to follow-up	0	3	3
Operation	6	3	9
Corticosteroid injection (second injection)	1	2	3
Platelet concentrate injection (second injection)	6	0	6
Lost to follow-up	1	0	1
Total	49	51	100

Six months after the procedure, PRP-treated patients reported a mean improvement of 53.5% (70.1 to 32.6) in their VAS scores compared with the initial values, whereas the corticosteroid-treated patients reported a 14.0% improvement (65.8 to 56.6; *P* < .001) (Figure 2). Also, after 6 months, DASH scores had improved 50.7% (161.3 to 79.5) in PRP patients versus a 10.7% improvement (131.3 to 117.3) in corticosteroid-treated patients (*P* = .003) (Figure 3).

One year after the procedure, PRP-treated patients reported a mean improvement of 63.9% (70.1 to 25.3) in their VAS scores compared with the initial values, whereas the corticosteroid-treated patients reported a 24.0% improvement (65.8 to 50.1; *P* < .001) (Figure 2). Also, after 1 year, DASH scores improved 66% (161.3 to 54.7) in PRP patients versus a 17.4% improvement (131.3 to 108.4) in corticosteroid-treated patients (*P* = .001) (Figure 3).

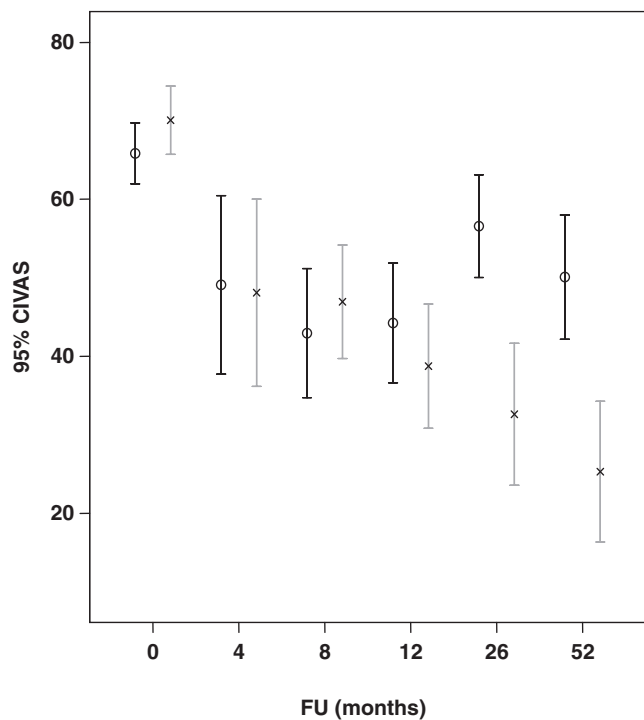
Regarding the patients who failed their treatment, those who crossed over to the PRP group and those who received surgery did finally benefit. The patients who received a reinjection with corticosteroids did not see a resolution of pain and disability, according to the mentioned criteria.

Successful treatment was defined as more than a 25% reduction in VAS or DASH score without a reintervention after 1 year. The results showed that 24 of the 49 patients (49%) in the corticosteroid group and 37 of the 51 patients (73%) in the PRP group were successful with the VAS score, which was significant (*P* < .001). Twenty-five of the 49 patients (51%) in the corticosteroid group and 37 of the 51 patients (73%) in the PRP group were successful with the DASH score, which was also significant (*P* = .005).

No fevers or rashes were reported. Apart from the local inflammation causing increased pain 3 to 4 weeks after the injection, no systemic or other local reactions were seen. The effect can be characterized as a local mechanism, without systemic side effects.

If we set the criteria for success at 50% or 75% improvement of both scores (instead of 25% improvement), the results still show significant differences between both groups, as shown in Tables 3 and 4.

Regarding the cost, PRP is not cost-effective when compared with corticosteroid on a short-term basis. A PRP treatment costs around €200 (current US\$300, as of November 2009). The DBC price for injection treatment



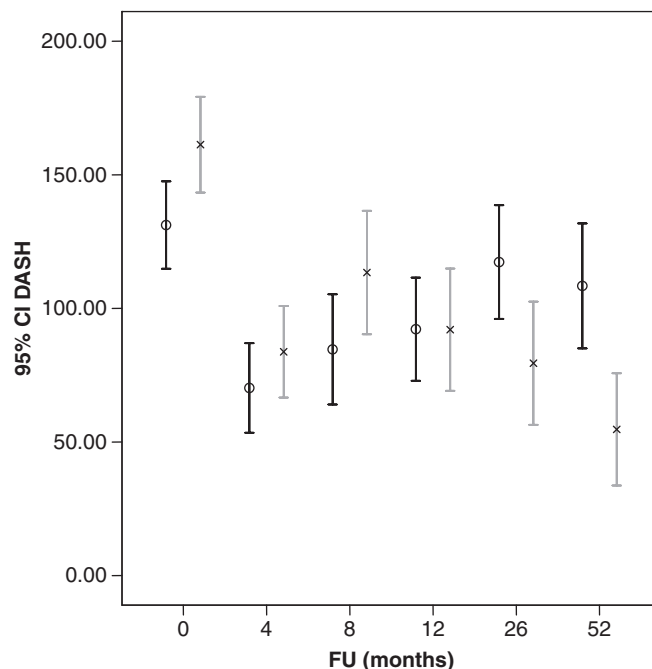
Time (wks)	CS	PRP
	Average ± SD	Average ± SD
VAS		
0	65.8 ± 13.8	70.1 ± 15.1
4	44.2 ± 26.4	55.4 ± 24.2
8	42.9 ± 29.2	46.9 ± 24.9
12	44.2 ± 27.1	38.7 ± 27.2
26	56.6 ± 23.2	32.6 ± 31.5
52	50.1 ± 28.1	25.3 ± 31.2

Figure 2. Twenty-four of the 49 patients (49%) in the corticosteroid (CS) group and 37 of the 51 patients (73%) in the platelet-rich plasma (PRP) group were defined as *successful* with the visual analog score (VAS), a significant difference ($P < .001$). CI, confidence interval. 0, CS; x, PRP.

is €360 (US\$540; DBC stands for Diagnose Behandelings Combinatie, or Diagnosis Treatment Combination). A DBC is an administrative code that combines diagnosis, treatment, and all the related costs; a DBC therefore includes all treatments per diagnosis, from the first visit to the last checkup. So the overall cost for a PRP injection will be around €560 (US\$840) compared with the corticosteroid injection of around €200 (US\$300). But this does not include all socioeconomic costs.

DISCUSSION

This randomized study was designed to test the use of concentrated autologous platelets in patients with lateral



t (wks)	CS	PRP
	Average ± SD	Average ± SD
DASH		
0	131.2 ± 58.2	161.3 ± 62.4
4	97.4 ± 69.0	135.9 ± 78.0
8	84.7 ± 73.4	113.4 ± 79.6
12	92.2 ± 68.7	92.0 ± 78.8
26	117.3 ± 75.6	79.5 ± 80.3
52	108.4 ± 82.2	54.7 ± 73.2

Figure 3. Twenty-five of the 49 patients (51%) in the corticosteroid (CS) group and 37 of the 51 patients (73%) patients in the platelet-rich plasma (PRP) group were defined as *successful* with the DASH Outcome Measure, a significant difference ($P = .005$). CI, confidence interval. 0, CS; x, PRP.

epicondylitis; its application proved to be both safe and easy. The corticosteroid group was actually better initially and then declined, whereas the PRP group progressively improved. There was a significant difference in decrease of pain and disability of function following the platelet application after 26 weeks and 1 year.

Lateral epicondylitis is a common problem with many available treatment methods. The most commonly recommended treatment is physiotherapy and bracing. Approximately 87% of the patients benefit from this combination of treatment methods.²⁰

Now controversial, corticosteroid injection was once considered the gold standard in the treatment of lateral epicondylitis. However, studies show that it is merely the best treatment option in the short-term, when compared with physiotherapy and wait-and-see policy. Poor results are often seen after the 12-week follow-up.¹⁸ Treatment with

TABLE 3
Pain Resolution for the Corticosteroid (CS) and Platelet-Rich Plasma (PRP) Groups

Time, wks	Group	n	Pain Reduction		Percentage Pain Reduction (%)				χ^2
			Average \pm SE	<i>t</i>	> 75%	50%-75%	25%-50%	< 25%	
4	CS	51	-21.6 \pm 3.5		17.6	15.7	19.6	47.1	.12
	PRP	48	-15.8 \pm 3.6	.14	4.2	10.4	29.2	56.3	
8	CS	51	-22.9 \pm 4.0		23.5	11.8	17.6	47.1	.22
	PRP	48	-22.9 \pm 3.5	.99	12.5	16.7	31.3	39.6	
12	CS	51	-21.6 \pm 3.6		15.7	21.6	15.7	47.1	.46
	PRP	48	-31.1 \pm 4.2	.09	18.8	33.3	14.6	33.3	
26	CS	51	-9.3 \pm 3.1		3.9	7.8	27.5	60.8	< .001
	PRP	49	-37.4 \pm 4.6	< .001	40.8	18.4	10.2	30.6	
52	CS	50	-15.7 \pm 3.5		13.7	9.8	23.5	52.9	< .001
	PRP	49	-44.8 \pm 4.4	< .001	57.1	8.2	10.2	24.5	

TABLE 4
Disability Resolution for the Corticosteroid (CS) and Platelet-Rich Plasma (PRP) Groups

Time, wks	Group	n	Disability Reduction		Percentage Disability Reduction (%)				χ^2
			Average \pm SE	<i>t</i>	> 75%	50%-75%	25%-50%	< 25%	
4	CS	51	-33.8 \pm 5.2		17.6	15.7	17.6	49.0	.12
	PRP	48	-24.6 \pm 6.4	.42	4.2	12.5	29.2	54.2	
8	CS	51	-46.5 \pm 6.7		29.4	9.8	17.6	43.1	.48
	PRP	48	-57.1 \pm 8.7	.96	16.7	14.6	20.8	47.9	
12	CS	51	-39.0 \pm 6.5		23.5	5.9	13.7	56.9	.05
	PRP	48	-68.5 \pm 9.7	.03	27.1	20.8	18.8	33.3	
26	CS	51	-13.8 \pm 7.7		13.7	7.8	11.8	66.7	.01
	PRP	49	-79.4 \pm 11.8	< .001	38.8	14.3	14.3	32.7	
52	CS	50	-22.4 \pm 8.6		24.0	12.0	14.0	50.0	.01
	PRP	49	-106.6 \pm 8.7	< .001	57.1	4.1	14.3	24.5	

corticosteroids has a high frequency of relapse and recurrence, probably because intratendinous injection may lead to permanent adverse changes within the structure of the tendon and because patients tend to overuse the arm after injection as a result of direct pain relief.¹⁸

In a meta-analysis, Smidt and colleagues¹⁷ showed that the effects of steroid injections—as compared with placebo injection, injection with local anesthetics, injection with another steroid, or another conservative treatment—are not significantly different in the intermediate and long-term. However, the patients who were examined all had short-term lateral epicondylitis.

There are various types of surgical procedures for patients with chronic lateral epicondylitis. Verhaar and colleagues noted an improvement in 60% to 70% of the patients after surgical treatment, although higher success rates (80% to 90%) have more recently been reported.^{21,23} Patients remain, however, interested in an alternative to surgical intervention.

Platelet-rich plasma is promoted as an ideal autologous biological blood-derived product that can be exogenously applied to various tissues where, after being activated, it releases high concentrations of platelet-derived growth factors that enhance tissue healing.^{5,26} With the Recover

System, the patient's own platelets can be collected into a highly concentrated formula. No activation agent was used during our procedure. The activation of the platelets will occur through the exposure of platelets to the thrombin, which is released from the tendon tissue during the pepping technique.

During the first 2 days of tendon healing, an inflammatory process is initiated by migration of neutrophils and, subsequently, macrophages to the degenerative tissue site. In turn, activated macrophages release multiple growth factors, including platelet-derived growth factor, transforming growth factors alpha and beta, interleukin-1, and fibroblast growth factor.⁴ Angiogenesis and fibroplasia start shortly after day 3, followed by collagen synthesis on days 3 to 5. This process leads to an early increase in tendon breaking strength, which is the most important tendon healing parameter, followed by epithelization and, ultimately, the remodeling process. This was confirmed in an animal study.¹

The treatment of tendinosis with an injection of concentrated autologous platelets may be a nonoperative alternative. Injection of autologous platelets has been shown to improve repair in tendinosis in several animal and in vitro models.^{9,15} A possible explanation for the long-lasting

effect of platelets could be that platelets improve the early neotendon properties so that the cells are able to perceive and respond to mechanical loading at an early time point.¹

The results of the present study confirm the suggested positive effect in vivo as described by Mishra and Pavelko.¹⁰ They reported a significant improvement of symptoms after 8 weeks in 60% of the patients treated with PRP versus 16% of the patients treated with a local anesthetic. After 6 months the improvement in patients treated with PRP was 81%. They compared PRP with a local anesthetic, which is not an accepted treatment for lateral epicondylitis in the Netherlands. Furthermore, they injected only 15 patients with PRP and compared them with 5 patients treated with a local anesthetic. The study was underpowered and the patients were not randomized.

Our results confirm the results of Edwards and Calandruccio.³ They injected whole blood into patients with lateral epicondylitis. Treatment success was seen in 79% of patients; however, multiple injections were necessary in 32% of patients. The limitation of this study is that all patients had failed previous nonsurgical treatments, including prior steroid injections. Furthermore, some patients had a beneficial effect after receiving more than 1 injection. In our study, a single percutaneous injection of PRP or corticosteroid was used with a peppering technique. Repeated injections might be beneficial in patients who had suboptimal results after the initial injection, although no evidence for a beneficial effect of more than one injection exists.

Twenty-six weeks (6 months) was chosen as the cutoff point to consider whether the therapy was successful or not; however, we achieved significant results after only 26 weeks. We know that the natural history of lateral epicondylitis predominantly results in healed patients (80%) within 1 year, but all patients in the present study had complaints for at least 6 months, thereby putting their improvement past the 1-year mark. In both the corticosteroid group and the PRP group, each patient has a natural history; as such and because the population was randomized, we can expect natural history to have the same influence on both groups.

In conclusion, this report describes the first comparison of an autologous platelet concentrate with the gold standard, corticosteroid injection, as a treatment for lateral epicondylitis in patients who have failed nonoperative treatment. It demonstrates that a single injection of concentrated autologous platelets improves pain and function more so than corticosteroid injection. These improvements were sustained over time with no reported complications. Perhaps for athletes it is less optimal, but all depends on the demands of the patient. We had no elite athletes in our population.

ACKNOWLEDGMENT

The study was sponsored by Biomet, Dordrecht, The Netherlands. The funding source had no involvement in study design; in the collection, analysis, and interpretation of data; in the writing of the report; and in the decision to

submit the work for publication. J.A.P. Hagenaars did the statistical analysis. He was an independent biostatistician from the Tilburg University, The Netherlands. He did not receive any funding for the statistical analysis. All authors declare that they participated in the writing of the article and that they saw and approved the final version. Taco Gosens declares that he had full access to all the data in the study and takes responsibility for the integrity of the data and the accuracy of the data analysis. This trial was registered with ClinicalTrials.gov (identifier: 2007-004947-31; <http://www.clinicaltrials.gov>).

REFERENCES

1. Aspenberg P, Virchenko O. Platelet concentrate injection improves Achilles tendon repair in rats. *Acta Orthop Scand*. 2004;75:93-99.
2. Assendelft WJ, Hay EM, Adsheed R, Bouter LM. Corticosteroid injections for lateral epicondylitis: a systematic overview. *Br J Gen Pract*. 1996;46:209-216.
3. Edwards SG, Calandruccio JH. Autologous blood injections for refractory lateral epicondylitis. *J Hand Surg [Am]*. 2003;28:272-278.
4. Everts PA, Hoffmann G, Wiebrich G, et al. Differences in platelet growth factor release and leucocyte kinetics during autologous platelet gel formation. *Transfus Med*. 2006;16:363-368.
5. Everts PA, Overvest EP, Jakimowicz JJ, et al. The use of autologous platelet-leukocyte gels in enhancing the healing process in surgery: a review. *Surg Endosc*. 2007;21:2063-2068.
6. Hay EM, Paterson SM, Lewis M, Hosie G, Croft P. Pragmatic randomized controlled trial of local corticosteroid injection and naproxen for treatment of lateral epicondylitis of elbow in primary care. *BMJ*. 1999;319:964-968.
7. Hong QN, Durand MJ, Loisel P. Treatment of lateral epicondylitis: where is the evidence? *Joint Bone Spine*. 2004;71:369-373.
8. Jobe FW, Ciccotti MG. Lateral and medial epicondylitis of the elbow. *J Am Acad Orthop Surg*. 1994;2:1-8.
9. Marx RE, Carlson ER, Eichstaedt RM, Schimmele SR, Strauss JE, Georgeff KR. Platelet-rich plasma: growth factor enhancements for bone grafts. *Oral Surg Oral Med Oral Pathol Oral Radiol Endod*. 1998;85:638-646.
10. Mishra A, Pavelko T. Treatment of chronic elbow tendinosis with buffered platelet-rich plasma. *Am J Sports Med*. 2006;34:1774-1778.
11. Molloy T, Wang Y, Murrell G. The roles of growth factors in tendon and ligament healing. *Sports Med*. 2003;33:381-394.
12. Nirschl R. Elbow tendinosis/tennis elbow. *Clin Sports Med*. 1992;11:851-870.
13. Nirschl RP, Pettrone FA. Tennis elbow: the surgical treatment of lateral epicondylitis. *J Bone Joint Surg Am*. 1979;61:832-839.
14. Samson S, Gerhardt M, Mandelbaum B. Platelet rich plasma injection grafts for musculoskeletal injuries: a review. *Curr Rev Musculoskelet Med*. 2008;1:165-174.
15. Sclafani AP, Romo T III, Ukrainsky G, et al. Modulation of wound response and soft tissue ingrowth in synthetic and allogeneic implants with platelet concentrate. *Arch Facial Plast Surg*. 2005;7:163-169.
16. Smidt N, Assendelft W, Arola H, et al. Effectiveness of physiotherapy for lateral epicondylitis: a systematic review. *Ann Med*. 2003;35:51-62.
17. Smidt N, Assendelft WJ, van der Windt DA, Hay EM, Buchbinder R, Bouter LM. Corticosteroid injections for lateral epicondylitis: a systematic review. *Pain*. 2002;96:23-40.
18. Smidt N, van der Windt DA, Assendelft WJ, Devillé WL, Korthals-de Bos IB, Bouter LM. Corticosteroid injections, physiotherapy, or a wait-and-see policy for lateral epicondylitis: a randomised controlled trial. *Lancet*. 2002;359:657-662.
19. Smith RW, Papadopolous E, Mani R, Cawley MI. Abnormal microvascular responses in lateral epicondylitis. *Br J Rheumatol*. 1994;33:1166-1168.

20. Struijs PA, Kerkhoffs GM, Assendelft WJ, Van Dijk CN. Conservative treatment of lateral epicondylitis: brace versus physical therapy or a combination of both. A randomized clinical trial. *Am J Sports Med.* 2004;32:462-469.
21. Thomas S, Broome G. Patient satisfaction after open release of common extensor origin in treating resistant tennis elbow. *Acta Orthop Belg.* 2007;73:443-445.
22. Veehof MM, Slegers EJ, van Veldhoven NH, Schuurman AH, van Meeteren NL. Psychometric qualities of the Dutch language version of the Disabilities of the Arm, Shoulder, and Hand questionnaire (DASH-DLV). *J Hand Ther.* 2002;15:347-354.
23. Verhaar J, Walenkamp G, Kester A, Van Mameren H, Van der Linden T. Lateral extensor release for tennis elbow: a prospective long-term follow-up study. *J Bone Joint Surg Am.* 1993;75:1034-1043.
24. Wang JH, Iosifidis MI, Fu FH. Biomechanical basis for tendinopathy. *Clin Orthop Relat Res.* 2006;443:320-332.
25. Wong SM, Hui AC, Tong PY, Poon DW, Yu E, Wong LK. Treatment of lateral epicondylitis with botulinum toxin: a randomized, double-blinded, placebo-controlled trial. *Ann Intern Med.* 2005;143:793-797.
26. Wrotniak M, Bielecki T, Gazdzik T. Current opinion about using the platelet-rich gel in orthopaedics and trauma surgery. *Ortop Traumatol Rehabil.* 2007;9:227-238.

For reprints and permission queries, please visit SAGE's Web site at <http://www.sagepub.com/journalsPermissions.nav>